

# Increased Expression of Inflammatory Cytokines and Matrix Metalloproteinases in Pseudophakic Corneal Edema

Yochai Shoshani,<sup>1</sup> Jacob Pe'er,<sup>1</sup> Victoria Doviner,<sup>2</sup> Joseph Frucht-Pery,<sup>1</sup> and Abraham Solomon<sup>1</sup>

**PURPOSE.** To evaluate the expression of inflammatory cytokines and matrix metalloproteinases in the corneal epithelium in pseudophakic corneal edema (PCE).

**METHODS.** Tissue sections were prepared from formalin-fixed, paraffin-embedded blocks of corneal buttons removed from 20 patients with PCE during penetrating keratoplasty (PKP) and from 11 age-matched control eyes enucleated because of uveal melanoma. Expression of interleukin (IL)-1 $\beta$ , -6, and -8; vascular endothelial growth factor (VEGF); and matrix metalloproteinase (MMP)-1, -3, and -9 proteins in the corneal epithelium was evaluated by immunohistochemistry. Digital image analysis was performed to quantify the expression of the various cytokines and MMPs. A mean intensity stain index (ISI), based on the staining density and the area stained, was calculated from digital images captured from sequential areas of the corneal epithelium.

**RESULTS.** The expression of most of the inflammatory cytokines and MMPs was significantly higher in the corneal epithelium of PCE corneal buttons than in the control specimens. MMP-9 had the highest expression when compared with the control (ISI =  $55.08 \pm 23.71$  in PCE compared with  $0.169 \pm 0.156$  in the control;  $P < 0.0001$ ). Significantly higher ISIs were also recorded for MMP-1 ( $16.14 \pm 8.49$  vs.  $1.13 \pm 1.79$ ;  $P < 0.0001$ ), IL-1 $\beta$  ( $62.62 \pm 27.23.97$  vs.  $1.61 \pm 1.27$ ;  $P < 0.0001$ ), IL-8 ( $37.91 \pm 21.18$  vs.  $4.24 \pm 3.60$ ;  $P < 0.0001$ ), and VEGF ( $81.67 \pm 26.22$  vs.  $19.40 \pm 16.85$ ;  $P = 0.0001$ ). The expression of MMP-3, IL-6, and TNF- $\alpha$  in PCE was not different from control expression. Significant positive correlations were found between the expression of IL-1 $\beta$  and MMP-9 ( $r^2 = 0.37$ ;  $P = 0.015$ ), between VEGF and IL-8 ( $r^2 = 0.22$ ;  $P = 0.042$ ), and a significant correlation was found between the expression of MMP-3 and TNF- $\alpha$  ( $r^2 = 0.5197$ ;  $P = 0.0007$ ). The expression of TNF- $\alpha$  correlated significantly with the patient's age ( $r^2 = 0.28$ ;  $P = 0.0195$ ).

**CONCLUSIONS.** The corneal epithelium in PCE expresses high levels of cytokines and matrix-degrading enzymes, which are associated with inflammation, wound healing, angiogenesis, and tissue degradation. The expression of these mediators may partially explain the pathologic features associated with this disease, such as bulla formation, recurrent epithelial desquamation, and corneal neovascularization. (*Invest Ophthalmol Vis Sci.* 2005;46:1940-1947) DOI:10.1167/iovs.04-1203

Pseudophakic corneal edema (PCE), formerly termed pseudophakic bullous keratopathy (PBK), is an iatrogenic corneal disease caused by corneal endothelial decompensation after various intraocular surgical procedures.<sup>1</sup> PCE usually follows cataract extraction with intraocular lens implantation and is currently one of the leading causes of corneal decompensation leading to penetrating keratoplasty (PKP).<sup>2</sup> PCE is characterized by chronic corneal stromal edema, with or without subepithelial bullae. As a result of the stromal and epithelial edema, Bowman's layer and the epithelial basement membrane attenuate or rupture,<sup>3,4</sup> leading to poor epithelial adhesion and formation of subepithelial bullae that continuously rupture, resulting in recurrent erosions and persistent epithelial defects, exposing the cornea at times to infectious ulcers. A vicious cycle of wound formation and wound healing results in a state of chronic inflammation.

Cytokines, growth factors, and matrix-degrading enzymes have an important role in ocular surface inflammation, wound healing, and angiogenesis. The corneal epithelium can produce many of these inflammatory mediators and at the same time is continuously exposed to cytokines and growth factors that are either present in the tear fluid or originate from corneal stromal fibroblasts. These mediators affect the corneal epithelial cells to produce inflammatory cytokines and mediators that further augment the inflammatory cycle. Results in studies have shown that corneal epithelial cells express interleukin (IL)-1 $\alpha$ , -1 $\beta$ , -6, and -8 and tumor necrosis factor (TNF)- $\alpha$ .<sup>5,6</sup> Complex relations occur between these inflammatory cytokines. IL-1 is a potent inducer of other inflammatory cytokines, such as IL-6 and -8, TNF- $\alpha$ , and granulocyte-macrophage colony-stimulating factor (GM-CSF).<sup>7</sup> A few previous studies on corneas from patients with PCE demonstrated increased expression of IL-1 $\alpha$  and -8,<sup>8</sup> and of bone morphogenetic protein (BMP)-4 and insulin-like growth factor (IGF)-I,<sup>9</sup> but these studies focused on the mRNA of these cytokines and did not investigate their protein expression.

In addition to cytokines and growth factors, several matrix-degrading enzymes participate in tissue degradation, which is associated with inflammation and wound healing. The matrix metalloproteinases (MMPs) are a group of proteolytic enzymes that function in the remodeling of tissues.<sup>10,11</sup> Their substrates include most of the extracellular matrix components, such as collagen, fibronectin, and laminin, as well as cytokines and cell surface molecules. A complex network of responses occurs between cytokines and MMPs in the ocular surface. MMPs activate cytokines such as transforming growth factor- $\beta$  (by

From the Departments of <sup>1</sup>Ophthalmology and <sup>2</sup>Pathology, Hadassah University Hospital, the Hebrew University-Hadassah School of Medicine, Jerusalem, Israel.

Presented at the annual meeting of the Association for Research in Vision and Ophthalmology, Fort Lauderdale, Florida, April 2004.

This study was performed as an MD thesis of the first author, as part of the requirements of the Hebrew University Medical School and Hadassah University Hospital, Jerusalem, Israel.

Submitted for publication October 9, 2004; revised December 25, 2004, and February 12, 2005; accepted February 14, 2005.

Disclosure: **Y. Shoshani**, None; **J. Pe'er**, None; **V. Doviner**, None; **J. Frucht-Pery**, None; **A. Solomon**, None

The publication costs of this article were defrayed in part by page charge payment. This article must therefore be marked "advertisement" in accordance with 18 U.S.C. §1734 solely to indicate this fact.

Corresponding author: Abraham Solomon, Cornea, External Eye Disease, and Refractive Surgery Service, Department of Ophthalmology, Hadassah University Hospital, Kiryat Hadassah, POB 12000, Ein-Kerem, Jerusalem 91120, Israel; avisol@md.huji.ac.il.

TABLE 1. Antibodies to Cytokines and MMPs and Treatment Conditions

Factor	Antibody/Clone	Concentration	Pretreatment	Positive Control
MMP-1	Mouse monoclonal/sc-21731	10 $\mu$ g/ml	10 minutes PK (1 $\mu$ g/mL) at room temperature	Breast carcinoma
MMP-3	Mouse monoclonal/sc-21732	10 $\mu$ g/ml	10 minutes PK (1 $\mu$ g/mL) at room temperature	Breast carcinoma
MMP-9	Mouse monoclonal/sc-21733	4 $\mu$ g/ml	10 minutes PK (1 $\mu$ g/mL) at room temperature	Breast carcinoma
VEGF	Mouse monoclonal/sc-7269	4 $\mu$ g/ml	7 minutes citrate solution ( $\times$ 100) in pressure cooker at 120°C*	Primary pterygium
IL-1 $\beta$	Mouse monoclonal/508A7G8+508A4A2	4 $\mu$ g/ml	10 minutes urea (6 M) at room temperature	Inflamed synovium
IL-6	Mouse monoclonal/677B6A2	20 $\mu$ g/ml	10 minutes urea (6 M) in pressure cooker at 90°C*	Inflamed synovium
IL-8	Mouse monoclonal/893C4G2	20 $\mu$ g/ml	10 minutes urea (6 M) in pressure cooker at 90°C*	Inflamed synovium
TNF- $\alpha$	Mouse monoclonal/68B2B3	20 $\mu$ g/ml	10 minutes urea (6 M) in pressure cooker at 90°C*	Inflamed synovium

\* Slides were left to cool at room temperature for 10 minutes.

The MMPs and VEGF were from Santa Cruz Biotechnology, Santa Cruz, CA; the ILs and TNF- $\alpha$  were from Biosource Europe, S.A.,

MMP-9),<sup>12</sup> and TNF- $\alpha$  (by MMP-3).<sup>13</sup> At the same time, the expression of MMPs can be upregulated by cytokines. Both IL-1 $\beta$  and TNF- $\alpha$  can upregulate several MMPs, including MMP-1, -3, -9, -11, and -13.<sup>14</sup> MMPs were implicated in the pathogenesis of several ocular surface and tear film disorders, such as sterile corneal ulceration,<sup>15</sup> recurrent epithelial erosions,<sup>16</sup> dry eye disorders associated with rheumatoid arthritis,<sup>17</sup> pterygium<sup>18</sup> (Lee S-B, et al. *IOVS* 1999;40:ARVO E-Abstract 1768), and conjunctival chalasis.<sup>19</sup>

The expression of proinflammatory cytokines and matrix-degrading enzymes in PCE has not been thoroughly investigated. Surprisingly, only a few studies have been undertaken to investigate selected cytokines and MMPs in PCE, and their focus was mRNA expression. This is the first study to present quantified data on the protein expression of the major inflammatory cytokines and matrix-degrading enzymes in the corneal epithelium in pseudophakic corneal edema and to study possible relations between these mediators.

## MATERIALS AND METHODS

### Patients and Tissues

The study adhered to the tenets of the Declaration of Helsinki. Central corneal buttons, measuring between 7.5 and 8.5 mm, were removed during PKP from patients with PCE. All corneal buttons were soaked in formaldehyde immediately after removal and transferred to the ophthalmic pathology laboratory at the Department of Ophthalmology, Hadassah University Hospital, for further processing.

The ophthalmic pathology laboratory log book was used to retrieve patients with the diagnosis of PCE. Twenty consecutive patients who had undergone PKP for PCE between January 2002 and December 2003 were thus retrieved. The clinical diagnosis of PCE was confirmed through a retrospective review of the clinical files of these patients. The diagnosis of PCE was based on the development of corneal decompensation within the first 3 months after cataract surgery, the presence of chronic corneal stromal and epithelial edema, and the absence of any evidence of Fuch's endothelial dystrophy in the fellow eye. All patients with PCE had had painful epithelial bullae with recurrent corneal erosions and had presented with signs and symptoms of chronic ocular irritation. Patients for whom the chart review findings did not meet the criteria for PCE were not included in the study. The patients' files were studied, and the age at the time of surgery, the types of intraocular lens used for the cataract surgery associated with PCE, and the time from cataract surgery to PKP were recorded for each patient.

The control group consisted of 11 age-matched eyes that were enucleated for uveal melanoma. The tissues were retrieved by referring to the log book of the ophthalmic pathology laboratory, and the

clinical diagnosis was confirmed retrospectively through clinical chart review of the respective patients. In all of these patients, the ocular surface was clinically normal, and none had presented with any signs or symptoms of ocular irritation. After enucleation, the whole globe was soaked in formaldehyde and transferred for processing in the ophthalmic pathology laboratory.

As a positive control for the inflammatory cytokines (IL-1 $\beta$ , -6, and -8 and TNF- $\alpha$ ) synovial tissue from patients with active rheumatoid arthritis was used. Tissue sections from breast carcinoma were used as positive controls for the matrix metalloproteinases (MMP-1, -3, and -9), and sections from primary pterygium were used as the positive control for VEGF (Table 1).

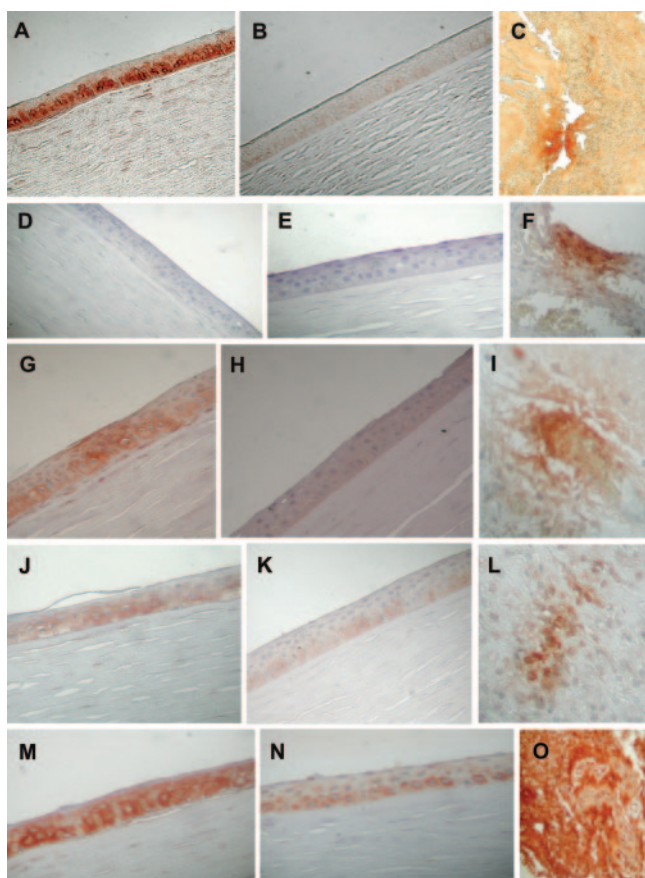
Negative control experiments were performed by omitting the primary antibody and incubating in antibody diluent and secondary antibody. Tissues were fixed, embedded in paraffin, and cut to slices of 4  $\mu$ m.

### Immunohistochemistry

Paraffin-embedded tissue blocks were deparaffinized and rehydrated through solutions of xylenes (three times for 5 minutes each), graded alcohol solutions (three times for 1 minute each, in 100% alcohol; 1 minute in 96% alcohol), and distilled water and phosphate buffer (PBS; two times for 5 minutes each). Pretreatment consisted of proteinase K (PK; 1  $\mu$ g/mL), citrate solution ( $\times$ 100), or 6 M urea depending on the primary antibody used (Table 1). Endogenous peroxidase activity was quenched by immersing the slides in 3% H<sub>2</sub>O<sub>2</sub> solution. The slides were then washed in PBS (two times for 5 minutes each) and blocked for nonspecific staining by nonimmune serum (Zymed, South San Francisco, CA) for 20 minutes. One of eight different primary antibodies (IL-1 $\beta$ , TNF- $\alpha$ , IL-6, IL-8, MMP-1, MMP-3, MMP-9, or VEGF) was then added at different final dilutions (Table 1) and the slides were incubated for 1 hour. Thereafter, the slides were washed in PBS (two times for 2 minutes each). The secondary antibody, labeled polymer HRP anti-mouse antibody (Dako, Carpinteria, CA), was added for 30 minutes, after which the slides were washed in PBS again (two times for 2 minutes each). Finally, the slides were developed in 3,3'-diaminobenzidine (DAB chromogen; Dako) for 5 minutes and counterstained with Mayer hematoxylin (Bioptica, Italy). Sections from PCE and control corneas were processed simultaneously with the same antibody, using the same treatment parameters, to obtain similar dye staining and background conditions for the PCE and normal cornea samples.

### Digital Image Analysis

Sequential images of microscopic sections in each coverslip were photographed within 72 hours after immunostaining by a digital camera (Coolpix 990; Nikon, Tokyo, Japan) mounted on a light microscope (Axiolab; Carl Zeiss Meditec, Jena, Germany) at a magnification of 40 $\times$ , and saved in jpg file format. The entire corneal epithelium was pho-



**FIGURE 1.** Immunohistochemical expression of inflammatory cytokines in the corneal epithelium of corneal buttons taken during PKP from patients with PCE. On each row of images, the *left* image shows the expression in PCE, the *middle* shows the staining of the same antibody in a normal cornea, and the *right* is a positive control for the same antibody in synovial tissue (C, F, I, L) or pterygium (O). (A–C) IL-1 $\beta$ , (D–F) IL-6, (G–I) IL-8, (J–L) TNF- $\alpha$ , and (M–O) VEGF staining. Positive staining was demonstrated for IL-1 $\beta$ , IL-8, and VEGF in the corneal epithelium in PCE.

tographed along a diameter of the corneal button. Images were then analyzed ImagePro-Plus software; Media Cybernetics, Silver Springs, MD), using a previously described protocol.<sup>20</sup> Briefly, the entire corneal epithelial layer in each image was marked, and the total marked area was calculated. The area stained by the antibody of interest was identified and calculated by using the software color cube algorithm. The integrated optical density (IOD), a measure of area and intensity of the staining by the antibody (area stained by antibody  $\times$  intensity of stain) was then calculated. The intensity score index (ISI) was calculated for each image with the formula  $ISI = IOD/\text{total area}$ . The ISIs for all the sequential images of each cornea and for each of the antibodies were averaged, and the mean ISI was the main outcome measure for each of the cytokines and MMPs investigated.

### Statistical Analysis

Mann-Whitney test was used to compare the mean ISIs between PBK and control corneas for each cytokine or MMP. Factor analysis was performed to produce a correlation matrix to screen for intercorrelations among the mean ISIs of the cytokines and MMPs and the clinical variables (age and time to PKP). Linear regression analysis was performed between pairs of variables for which a significant correlation was found based on the factor analysis, performed on computer (GB-Stat, ver. 10.0; Dynamic Microsystems, Silver Spring, MD; Prism, ver. 4.0; GraphPad Software, San Diego, CA).

### RESULTS

The mean age of the patients with PCE was  $66.7 \pm 13.5$  years (range, 36–87), whereas the mean age of the control group was  $62.7 \pm 14.7$  years (range, 37–77, no significant difference). Of the 20 patients with PCE, 11 had undergone posterior chamber intraocular lens (IOL) implantation, and 9 had undergone anterior chamber IOL implantation. The mean period between cataract surgery and PKP was  $8.4 \pm 6.6$  years (range, 3 months to 23 years).

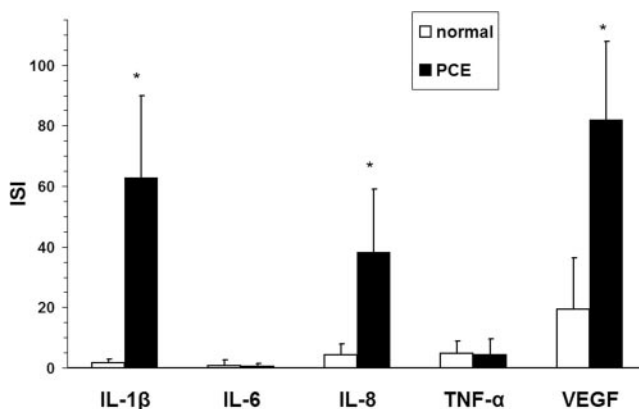
The corneal epithelium of corneal buttons from patients with PCE demonstrated a marked expression of IL-1 $\beta$  (Fig. 1A), IL-8 (Fig. 1G), and VEGF (Fig. 1M), whereas a mild expression was evident for TNF- $\alpha$  (Fig. 1J) and almost no expression was demonstrated for IL-6 (Figs. 1D). The main location of IL-1 $\beta$ , IL-8, and TNF- $\alpha$  was in the basal layers of the epithelium, whereas the expression of VEGF was evident in all the layers of the corneal epithelium (Fig. 1M).

Computerized digital analysis of the staining area and intensity of the different antibodies demonstrated a significantly increased expression of IL-1 $\beta$ , IL-8, and VEGF in PCE corneas compared with control corneas (Fig. 2). The mean ISIs for IL-1 $\beta$ , IL-8, and VEGF were 38.9-, 8.9-, and 4.2-fold higher, respectively, in PCE corneas than in control corneas ( $P < 0.0001$ ; Table 2). No differences were demonstrated between PCE and normal corneas in the expression of both IL-6 and TNF- $\alpha$  (Table 2).

Among the MMPs, MMP-1 and -9 had significantly higher expression in the corneal epithelium of patients with PCE compared with control subjects (Figs. 3A, 3G; Fig. 4). The mean ISIs of MMP-1 and -9 were 14.2- and 325-fold higher than those of the control corneas, respectively ( $P < 0.0001$ ; Fig. 4). The staining of the MMPs was confined to the basal layers of the corneal epithelium (Fig. 3). The expression of MMP-3 was low and not different from the expression in the control corneas (Figs. 3D, 4).

Factor analysis of the mean ISIs of all the studied cytokines and MMPs (Table 3) revealed significant intercorrelations between the mean ISIs of IL-1 $\beta$  and MMP-9 (0.611;  $P < 0.05$ ), between IL-8 and VEGF (0.4898;  $P < 0.05$ ), between MMP-3 and TNF- $\alpha$  (0.7209;  $P < 0.05$ ), and between the patient's age and the mean ISI of TNF- $\alpha$  (0.5304,  $P < 0.05$ ).

Linear regression analyses were performed to validate the association between these variables. A significant correlation



**FIGURE 2.** Expression of inflammatory and angiogenic mediators in the corneal epithelium in PCE compared with normal corneas. Immunostained sections were digitally photographed and scanned. The stained area and staining intensity were analyzed to yield the ISI for each sample. Data represent the mean  $\pm$  SD of ISIs from 20 patients with PCE or 11 patients with normal corneas, respectively ( $*P < 0.0001$ ; Mann-Whitney test).



TABLE 2. ISIs of Cytokines and MMPs in PCE and Normal Corneas

Cytokine/MMP	Normal	PCE	Increase (x)	P
IL-1 $\beta$	1.609 $\pm$ 1.268	62.624 $\pm$ 27.234	38.9	<0.0001
IL-6	0.835 $\pm$ 1.883	0.563 $\pm$ 0.829	0.67	0.0546
IL-8	4.240 $\pm$ 3.602	37.914 $\pm$ 21.183	8.9	<0.0001
TNF- $\alpha$	4.790 $\pm$ 3.943	4.363 $\pm$ 5.157	0.91	0.3974
VEGF	19.400 $\pm$ 16.846	81.668 $\pm$ 26.220	4.2	<0.0001
MMP-1	1.133 $\pm$ 1.786	16.141 $\pm$ 8.492	14.2	<0.0001
MMP-3	2.345 $\pm$ 1.942	1.836 $\pm$ 2.791	0.78	0.2699
MMP-9	0.169 $\pm$ 0.156	55.083 $\pm$ 23.711	325.9	<0.0001

Data are the mean ISI  $\pm$  SD for each cytokine and MMP in PCE and normal corneas. Significance was determined by the Mann-Whitney test.

was found between the mean ISIs of IL-1 $\beta$  and MMP-9 ( $r^2 = 0.37$ ;  $P = 0.015$ ; Fig. 5). Similarly, a significant correlation was demonstrated between the expression of IL-8 and VEGF ( $r^2 = 0.22$ ;  $P = 0.042$ ; Fig. 6). A significant correlation was found between the ISIs of MMP-3 and TNF- $\alpha$  ( $r^2 = 0.5197$ ;  $P = 0.0007$ ; Fig. 7). In addition, the mean ISI of TNF- $\alpha$  was found to correlate significantly with the patient's age ( $r^2 = 0.28$ ;  $P = 0.0195$ ; Fig. 8). Because TNF- $\alpha$  was the only cytokine with expression that correlated significantly with age and because the mean ISI of this cytokine did not differ between PCE and control specimens, we studied whether this correlation with age would be true also of the control samples. A linear regression analysis between the ages of the control samples and their TNF- $\alpha$  ISIs revealed no significant correlation ( $r^2 = 0.0089$ ;  $P = 0.81$ ).

## DISCUSSION

In this study, we found an increased expression of IL-1 $\beta$ , IL-8, VEGF, MMP-1, and MMP-9 in the corneal epithelium in PCE—

significantly higher than in corneas with no apparent disease. According to digital analysis of the stained areas, the mean expression of MMP-9, one of the major matrix-degrading enzymes in the ocular surface, correlated significantly with that of IL-1 $\beta$ , one of the most potent proinflammatory cytokines secreted by the corneal epithelium. A positive correlation was also found between the expression of IL-8 and VEGF, which are both potent angiogenic cytokines. In addition, the expression of TNF- $\alpha$  was directly and significantly correlated with the patient's age, an association that was not found in normal corneas.

The role of inflammatory cytokines and MMPs in various inflammatory conditions of the ocular surface has been studied before. The normal corneal epithelium has the ability to produce proinflammatory cytokines such as IL-1,<sup>21</sup> IL-6,<sup>22</sup> and IL-8.<sup>23</sup> IL-1 often initiates the inflammatory cascade and stimulates the release of IL-6, IL-8, and TNF- $\alpha$ . TNF- $\alpha$  is not normally expressed in the corneal epithelium, and its source is mainly keratinocytes and inflammatory cells such as macrophages and lymphocytes. Most of these cytokines participate in corneal wound healing, which most probably occurs in PCE when recurrent corneal erosions appear. IL-1 initiates the repair of the corneal epithelium by promoting the production of a host of cytokines and growth factors<sup>5,24,25</sup> that induce corneal epithelial cell proliferation and wound healing. IL-6 and TNF- $\alpha$  also participate in corneal wound healing.<sup>26</sup>

Two previous studies have been conducted to investigate the mRNA expression of IL-1 $\alpha$  and -8 in PCE compared with normal corneas. One of these studies demonstrated with semi-

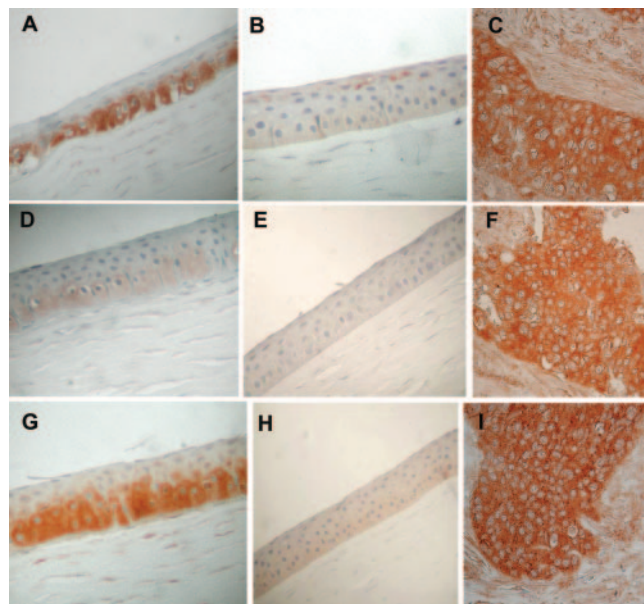


FIGURE 3. Immunohistochemical expression of MMPs in the corneal epithelium of corneal buttons taken during PKP from patients with PCE. In each row, the *left* image shows expression in PCE, the *middle* image shows the staining of the same antibody in a normal cornea, and the *right* image is a positive control for the same antibody in breast carcinoma. (A–C) MMP-1, (D–F) MMP-3, (G–I), and MMP-9 staining. Positive staining was demonstrated for both MMP-1 and -9 in the corneal epithelium in PCE.

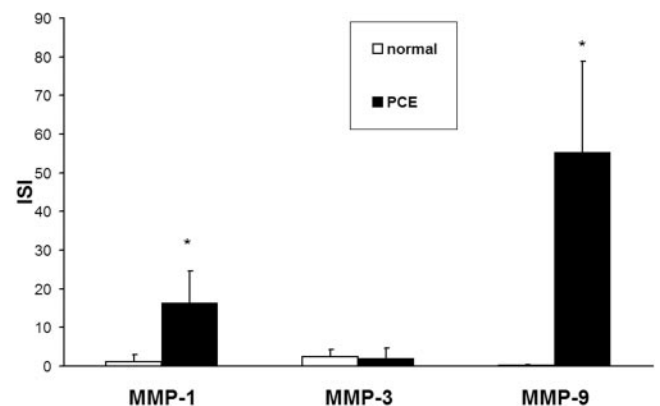


FIGURE 4. Expression of MMPs in the corneal epithelium in PCE compared with normal corneas. Immunostained sections were digitally photographed and scanned. The stained area and staining intensity were analyzed to yield the ISI for each sample. Data represent the mean  $\pm$  SD of ISIs from 20 patients with PCE or 11 patients with normal corneas, respectively ( $*P < 0.0001$ ; Mann-Whitney test).

TABLE 3. Correlation Matrix of ISI of Cytokines and MMPs and Clinical Parameters of Patients with PCE

Variable	Age	Time to PKP	IL-1 $\beta$	IL-6	IL-8	TNF- $\alpha$	VEGF	MMP-1	MMP-3	MMP-9
Age	1	-0.1965	-0.0522	-0.0976	0.0377	0.5304*	-0.0833	-0.2550	0.2279	0.0706
Time to PKP	0.1965	1	-0.0235	-0.2200	0.2424	0.3359	0.0974	-0.4019	0.4839	0.1044
IL-1 $\beta$	-0.0522	-0.0234	1	0.4347	0.3025	0.1359	0.1667	0.1189	0.1635	0.6110*
IL-6	-0.0976	-0.2200	0.4347	1	0.0246	-0.1103	0.0031	-0.3131	0.0217	0.3563
IL-8	0.0374	0.2423	0.3025	0.0246	1	0.1569	0.4898*	-0.2797	0.2418	0.2343
TNF- $\alpha$	0.5304*	0.3359	0.1359	-0.1103	0.1570	1	0.0497	-0.4097	0.7209*	0.1469
VEGF	-0.0833	0.0974	0.1667	0.0031	0.4898*	0.0497	1	-0.2119	0.1705	-0.0748
MMP-1	-0.2551	-0.4019	0.1190	-0.3131	-0.2797	-0.4097	-0.2120	1	-0.1737	-0.0144
MMP-3	0.2279	0.4839	0.1635	0.0217	0.2418	0.7209*	0.1705	-0.1737	1	0.4314
MMP-9	0.0706	0.1043	0.6110*	0.3564	0.2343	0.1469	-0.0748	-0.0145	0.4314	1

\* $P < 0.05$ .

quantitative RT-PCR an increased expression of both IL-1 $\alpha$  and -8 mRNA in PCE.<sup>9</sup> However, these differences were not found to be significant in that study. Another study demonstrated significantly higher expression of IL-1 $\alpha$  and -8 in PCE using regular RT-PCR. In none of these studies, however, was the protein expression of these cytokines investigated.

Corneal angiogenesis in PCE may be associated with chronic inflammation, after multiple episodes of corneal epithelial wound healing and repair or after infectious keratitis. Two of the cytokines in our study, IL-8 and VEGF, are associated with angiogenesis. VEGF is known to be constitutively expressed in the normal corneal epithelium and to be upregulated after trauma.<sup>27</sup> Several studies have demonstrated a role for VEGF in corneal neovascularization in various animal models of ocular surface inflammation.<sup>28-30</sup> IL-8 is another potent cytokine, known to promote angiogenesis by enhancing survival and proliferation of vascular endothelial cells,<sup>31</sup> and also to play a role in various models of corneal inflammation,<sup>32-34</sup> and to promote corneal neovascularization.<sup>35</sup> No studies so far have demonstrated either IL-8 or VEGF in the corneal epithelium of corneas with PCE. In fact, the expression of VEGF mRNA was significantly lower in PCE than in normal corneas in one report.<sup>9</sup> We found both IL-8 and VEGF proteins to be highly expressed in the corneal epithelium of PCE compared with the control. Moreover, we found a positive and significant correlation between the expression values of these two angiogenic cytokines (Fig. 6), suggesting that a common pathway may be involved in the regulation of both IL-8 and VEGF in corneal inflammation. One possibility for such a common path-

way is IL-1, which was recently found to be an inducer of VEGF production<sup>36,37</sup> and is also known to be a potent inducer of IL-8 in the corneal epithelium.<sup>23</sup>

MMPs are a family of extracellular proteinases that degrade extracellular matrix proteins. The MMPs have a pivotal role in a number of pathologic processes, including angiogenesis and wound healing, where matrix degradation takes place.<sup>11,38,39</sup> The MMP family includes at least 22 different proteinases and is divided into five subfamilies, including the gelatinases, collagenases, stromelysins, membrane-type MMPs, and others. Several members of this family of highly regulated enzymes, specifically MMP-1, -3 and -9, have been implicated in the pathogenesis of keratoconjunctivitis sicca, conjunctival chalasis, pterygium, and vernal keratoconjunctivitis.<sup>14,40,41</sup> Among the gelatinases, MMP-9 (gelatinase B) has been found to be one of the major degrading enzymes in ocular surface inflammation. MMP-9 is capable of degrading epithelial basement membrane components,<sup>42</sup> it is synthesized at the leading edge of the migrating corneal epithelium in wound healing,<sup>43</sup> it is overexpressed in sterile corneal ulceration,<sup>44</sup> and it is found in high levels in tears of patients with recurrent corneal erosions.<sup>45</sup> In our study, MMP-9 was found to be the most expressed mediator in PCE compared with the normal cornea (Table 2). A previous report failed to demonstrate MMP-9 in corneas with PCE.<sup>46</sup> However this seems to have been a result of a technical problem, as the corneal epithelium is capable of producing MMP-9 under inflammatory stimuli.<sup>47</sup>

Both IL-1 $\beta$  and TNF- $\alpha$  were found to modulate MMP-9 production by the corneal epithelium.<sup>47</sup> This role of IL-1 $\beta$  as a potent inducer of MMP-9 was reflected in our demonstration of

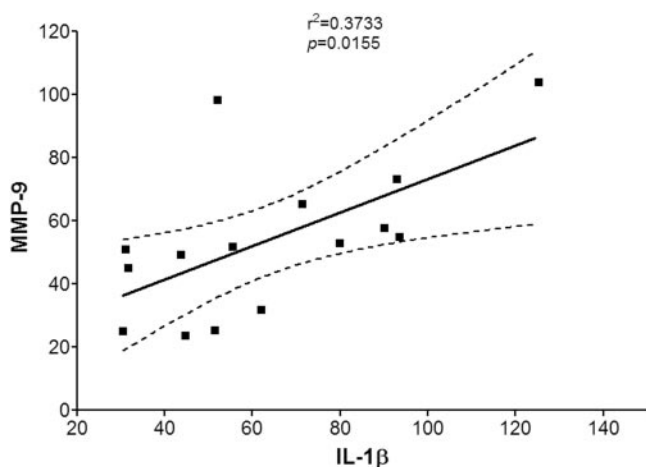


FIGURE 5. Linear regression analysis of ISIs of IL-1 $\beta$  and MMP-9 in PCE. A significant positive correlation is demonstrated between the expression of MMP-9 and IL-1 $\beta$ .

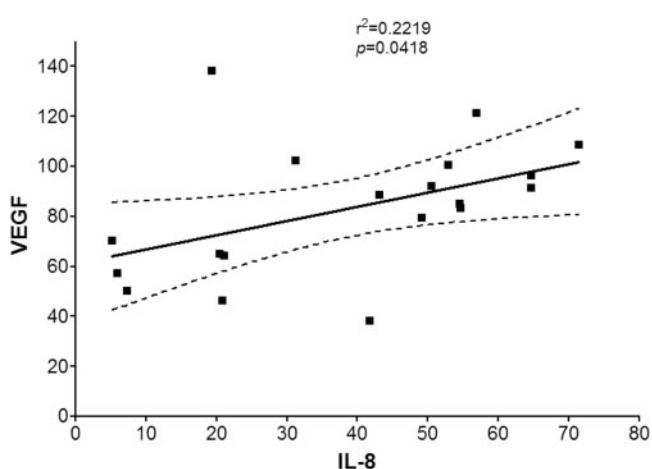


FIGURE 6. Linear regression analysis of ISIs of IL-8 and VEGF in PCE. A significant positive correlation is demonstrated between the expression of VEGF and IL-8.

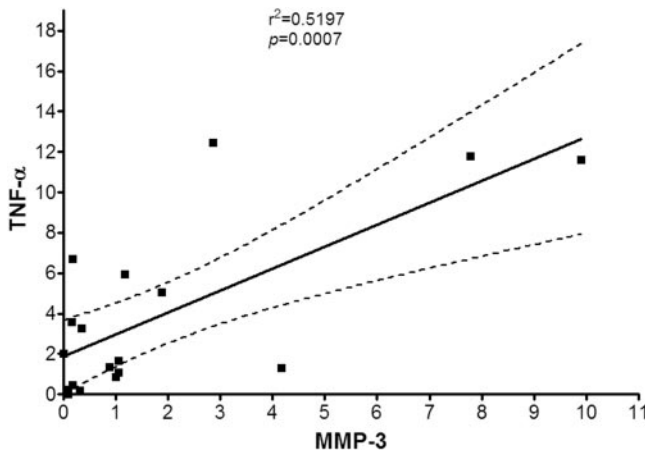


FIGURE 7. Linear regression analysis of ISIs of MMP-3 and TNF- $\alpha$  in PCE. A significant positive correlation was demonstrated between the expression of TNF- $\alpha$  and MMP-3.

a significant positive correlation between the expression levels of the MMP-9 and IL-1 $\beta$  proteins in the corneal epithelium (Fig. 5). This correlation suggests that in PCE the increased expression of IL-1 $\beta$  by the corneal epithelium as a result of the recurrent insults to the integrity of the epithelium induces the epithelial cells to express MMP-9, which further participates in the degradation of the epithelial basement membrane and the anterior corneal stroma.

MMP-1 (collagenase 1, a member of the collagenase family) has been found in pterygium head fibroblasts and in conjunctival chalasis fibroblasts, but has never been associated before with PCE. Like MMP-9 it is highly regulated by both IL-1 $\beta$  and TNF- $\alpha$ .<sup>14</sup> MMP-1 cleaves collagens type I, II, and III and, as do other members of the collagenase family, participates in vascularization, wound healing, and inflammatory processes and therefore may have a role in the process of tissue degradation and repair in PCE.

We found a high correlation between the expression of MMP-3 and TNF- $\alpha$  (Fig. 7). Of note, MMP-3 and TNF- $\alpha$  can modulate each other. TNF- $\alpha$  is known to be a potent stimulator of MMP-3 transcription.<sup>48,49</sup> At the same time, MMP-3 cleaves the precursor form of TNF- $\alpha$  to its active form. The cleavage site of MMP-3 in TNF- $\alpha$  is identical with the site used by TNF- $\alpha$  converting enzyme, which is one of the most potent activators of TNF- $\alpha$ .<sup>50</sup> In addition, pharmacological blocking of TNF- $\alpha$  at the protein level by its receptor causes downregulation of MMP-3 as well.<sup>51</sup> These studies explain why MMP-3 and TNF- $\alpha$  are frequently coexpressed in areas with ongoing inflammation and tissue degradation and are further supported by our data, showing these two mediators to be highly correlated in our tissue specimens in PCE.

Analysis of the correlation between age and cytokine expression revealed that a higher TNF- $\alpha$  expression correlated significantly with a patient's advanced age (Fig. 8). This association between advanced age and higher TNF- $\alpha$  expression has been reported in other clinical and laboratory models. Age has been found to be significantly associated with plasma levels of circulating TNF- $\alpha$  protein in humans<sup>52</sup> as well as in mice.<sup>53</sup> Production of TNF- $\alpha$  by peritoneal macrophages from both male and female mice increases significantly with aging.<sup>54</sup> The increase of TNF- $\alpha$  expression with age in our study suggests that the patient's age may be an important factor that aggravates the overall inflammatory response in PCE. A possible explanation for this finding, which was not demonstrated in the normal corneas, is the decreased endothelial cell count in older patients, which when coupled with surgical damage

leading to PCE, is responsible for a more pronounced corneal stromal edema and hence a more intense inflammatory response in the corneal epithelium.

Digital image analysis was used in this study to quantify the protein expression of several proinflammatory cytokines and matrix-degrading enzymes. This method was extremely sensitive and useful for the detection of selected mediators and for cross-correlations between mediators that work in concert in the processes of wound healing, inflammation, and angiogenesis. This is the first study that demonstrates in a quantified manner the protein expression of inflammatory mediators in PCE, and shows significant correlations between mediators that are known to regulate each other and to be coexpressed in inflamed tissues. Digital quantification of protein expression may also be valuable for screening the expression of multiple samples simultaneously, such as protein array analysis, and for screening possible relations between mediators in a complex network of responses.

The clinical implications of our data relate to the understanding of the crucial roles that these cytokines and degrading enzymes play in corneal disease. The association between some of the inflammatory cytokines (such as IL-1 $\beta$  and TNF- $\alpha$ ) and the matrix-degrading enzymes (such as MMP-9) has been previously demonstrated in various *in vitro* and *in vivo* models, including the corneal epithelium.<sup>47,55-58</sup> In addition, the deleterious effects of MMP-9 on the corneal epithelium and its basement membrane were shown.<sup>42,44,59</sup> Reports have shown that Bowman's layer and the epithelial basement membrane attenuate or rupture in PCE.<sup>3,4,60</sup> Taken together, these studies show that MMP-9 has a role in the disruption of the basement membrane and the integrity of the corneal epithelium, thereby attenuating the adhesion of the corneal epithelium, creating epithelial bullae and recurrent corneal erosions. Our data demonstrate the presence of MMP-9 in PCE and show a direct correlation between the expression of MMP-9 and IL-1 $\beta$ , thereby linking the known effects of IL-1 $\beta$  and MMP-9 on the corneal basement membrane and epithelium, with the tissue expression of these mediators in PCE.

The ability to suppress inflammatory mediators in the corneal epithelium was recently demonstrated in several *in vitro* models. In a recent study in cultured corneal epithelial cells, the expression of IL-1 $\beta$  was significantly suppressed by both methylprednisolone and doxycycline.<sup>61</sup> The functional activity of IL-1 $\beta$  in this model was evaluated by adding the conditioned media from these cultures containing the corneal-epithelium-derived IL-1 $\beta$  to corneal fibroblasts and measuring the resulting

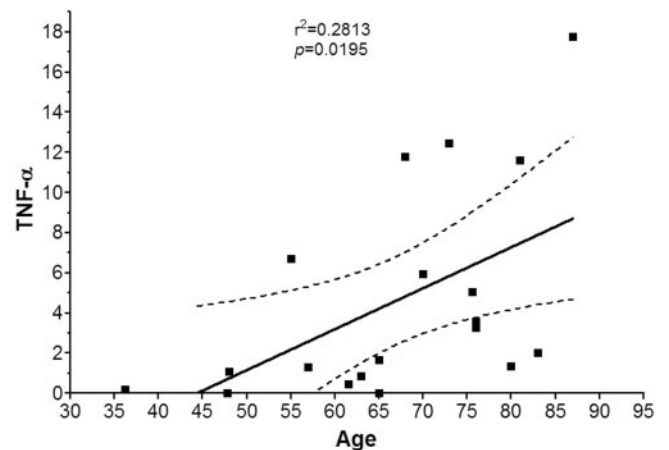


FIGURE 8. Linear regression analysis of ISIs of TNF- $\alpha$  and the patient's age in PCE. A significant positive correlation is demonstrated between age and TNF- $\alpha$  expression in PCE.



expression of MMP-1 and -3. The expression of both MMP-1 and -3 was found to correspond to the levels of IL-1 $\beta$ —namely, to be downregulated by treatment with either methylprednisolone or doxycycline.<sup>61</sup> Treatment of stimulated corneal epithelial cultures with doxycycline resulted in a lower concentration and activity of MMP-9.<sup>47,62</sup> An additional study demonstrated that IL-1 $\beta$  and TNF- $\alpha$  upregulate MMP-1 and -3 in human corneal epithelial cells. Doxycycline suppressed the stimulated MMP-1 at the mRNA and protein levels.<sup>14</sup> These studies show that inflammatory cytokines and matrix-degrading enzymes that are expressed in the inflamed corneal epithelium can be suppressed at the protein level by corticosteroids or by doxycycline.

The high expression of inflammatory mediators and tissue degrading enzymes in PCE implies that anti-inflammatory treatment may be indicated in these patients while they await corneal transplantation. Although PKP is the definitive option for most of these patients, surgery may be delayed depending on tissue availability. Other patients may wait until a decision is made to operate, in cases where the indication for surgery is borderline (e.g., the corneal edema is moderate) and there is hope for a spontaneous resolution. In other patients, there is no indication for corneal transplantation because of the limited visual potential that results from macular edema. These conditions may expose many patients with PCE to prolonged periods of chronic corneal edema, with formation of bullae and repeated corneal erosions associated with significant ocular irritation and pain. In addition, repeated corneal erosions may expose patients to microbial keratitis. For these reasons, maintaining such patients on topical systemic anti-inflammatory agents, such as corticosteroids and tetracyclines, is crucial in taming inflammation and preventing its consequences.

In conclusion, our study demonstrated an increased expression of several proinflammatory mediators at the protein level in the corneal epithelium of PCE. These cytokines and matrix-degrading enzymes participate in the pathologic processes in PCE and specifically contribute to the continuous degradation of Bowman's layer and recurrent erosions of the corneal epithelium. Knowledge of the mediators involved in PCE and other chronic inflammatory ocular surface diseases may assist in selective targeting of these cytokines and enzymes pharmacologically and maintain the health of the corneal epithelium when corneal transplantation is not an option.

## References

- Cohen EJ, Brady SE, Leavitt K, et al. Pseudophakic bullous keratopathy. *Am J Ophthalmol*. 1988;106:264-269.
- Dobbins KR, Price FW Jr, Whitson WE. Trends in the indications for penetrating keratoplasty in the midwestern United States. *Cornea*. 2000;19:813-816.
- Kenyon KR. The synthesis of basement membrane by the corneal epithelium in bullous keratopathy. *Invest Ophthalmol Vis Sci*. 1969;8:156-168.
- Ljubimov AV, Burgeson RE, Butkowski RJ, et al. Extracellular matrix alterations in human corneas with bullous keratopathy. *Invest Ophthalmol Vis Sci*. 1996;37:997-1007.
- Weng J, Mohan RR, Li Q, Wilson SE. IL-1 upregulates keratinocyte growth factor and hepatocyte growth factor mRNA and protein production by cultured stromal fibroblast cells: interleukin-1 $\beta$  expression in the cornea. *Cornea*. 1997;16:465-471.
- Kinoshita S, Adachi W, Sotozono C, et al. Characteristics of the human ocular surface epithelium. *Prog Retin Eye Res*. 2001;20:639-673.
- Torres PF, Kijlstra A. The role of cytokines in corneal immunopathology. *Ocul Immunol Inflamm*. 2001;9:9-24.
- Rosenbaum JT, Planck ST, Huang XN, et al. Detection of mRNA for the cytokines, interleukin-1 alpha and interleukin-8, in corneas from patients with pseudophakic bullous keratopathy. *Invest Ophthalmol Vis Sci*. 1995;36:2151-2155.
- Saghizadeh M, Chwa M, Aoki A, et al. Altered expression of growth factors and cytokines in keratoconus, bullous keratopathy and diabetic human corneas. *Exp Eye Res*. 2001;73:179-189.
- Murphy G, Docherty AJP. The matrix metalloproteinases and their inhibitors. *Am J Respir Cell Mol Biol*. 1992;7:120-125.
- Woessner JF Jr. Matrix metalloproteinases and their inhibitors in connective tissue remodeling. *FASEB J*. 1991;5:2145-2154.
- Yu Q, Stamenkovic I. Cell surface-localized matrix metalloproteinase-9 proteolytically activates TGF-beta and promotes tumor invasion and angiogenesis. *Genes Dev*. 2000;14:163-176.
- Gearing AJ, Beckett P, Christodoulou M, et al. Processing of tumour necrosis factor-alpha precursor by metalloproteinases. *Nature*. 1994;370:555-557.
- Li D-Q, Shang TY, Kim HS, et al. Regulated expression of collagenases MMP-1, -8, and -13 and stromelysins MMP-3, -10, and -11 by human corneal epithelial cells. *Invest Ophthalmol Vis Sci*. 2003;44:2928-2936.
- Kervick GN, Pflugfelder SC, Haimovici R, et al. Paracentral rheumatoid corneal ulceration: clinical features and cyclosporine therapy. *Ophthalmology*. 1992;99:80-88.
- Darsun D, Kim MC, Solomon A, Pflugfelder SC. Treatment of recalcitrant recurrent corneal erosions with inhibitors of matrix metalloproteinase-9, doxycycline and corticosteroids. *Am J Ophthalmol*. 2001;132:8-13.
- Smith VA, Rishmawi H, Hussein H, Easty DL. Tear film MMP accumulation and corneal disease. *Br J Ophthalmol*. 2001;85:147-153.
- Solomon A, Li D-Q, Lee S-B, Tseng SCG. Regulation of collagenase, stromelysin, and urokinase-type plasminogen activator in primary pterygium body fibroblasts by inflammatory cytokines. *Invest Ophthalmol Vis Sci*. 2000;41:2154-2163.
- Meller D, Li D-Q, Tseng SCG. Regulation of collagenase, stromelysin, and gelatinase B in human conjunctival and conjunctivochalasis fibroblasts by interleukin-1 $\beta$  and tumor necrosis factor- $\alpha$ . *Invest Ophthalmol Vis Sci*. 2000;41:2922-2929.
- Albaugh G, Kann B, Strande L, et al. Nicotine induces endothelial TNF-alpha expression, which mediates growth retardation in vitro. *J Surg Res*. 2001;99:381-384.
- Wilson SE, He Y-G, Lloyd SA. EGF, EGF receptor, basic FGF, TGF-beta-1, and IL-1 alpha mRNA in human corneal epithelial cells and stromal fibroblasts. *Invest Ophthalmol Vis Sci*. 1992;33:1756-1765.
- Cubitt CL, Lausch RN, Oakes JE. Differences in interleukin-6 gene expression between cultured human corneal epithelial cells and keratocytes. *Invest Ophthalmol Vis Sci*. 1995;36:330-336.
- Einer VM, Strieter RM, Pavilack MA, et al. Human corneal interleukin-8: IL-1 and TNF-induced gene expression and secretion. *Am J Pathol*. 1991;139:977-988.
- Chedid M, Rubin JS, Csaky KG, Aaronson SA. Regulation of keratinocyte growth factor gene expression by interleukin 1. *J Biol Chem*. 1994;269:10753-10757.
- Wilson SE, Walker JW, Chwang EL, He Y-G. Hepatocyte growth factor, keratinocyte growth factor, their receptors, fibroblast growth factor receptor-2, and the cells of the cornea. *Invest Ophthalmol Vis Sci*. 1993;34:2544-2561.
- Kovalchuk LV, Khoroshilova-Maslova IP, Gankovskaya LV, et al. Natural complex of cytokines is a potent stimulant to posttraumatic regeneration in rabbit cornea. *J Ocul Pharmacol Ther*. 1996;12:271-279.
- van Setten GB. Vascular endothelial growth factor (VEGF) in normal human corneal epithelium: detection and physiological importance. *Acta Ophthalmol Scand*. 1997;75:649-652.
- Joussen AM, Poulaki V, Mitsiades N, et al. VEGF-dependent conjunctivalization of the corneal surface. *Invest Ophthalmol Vis Sci*. 2003;44:117-123.
- Lai CM, Spilbury K, Brankov M, et al. Inhibition of corneal neovascularization by recombinant adenovirus mediated antisense VEGF RNA. *Exp Eye Res*. 2002;75:625-634.
- Mastyugin V, Mosaed S, Bonazzi A, et al. Corneal epithelial VEGF and cytochrome P450 4B1 expression in a rabbit model of closed eye contact lens wear. *Curr Eye Res*. 2001;23:1-10.
- Li A, Dubey S, Varney ML, et al. IL-8 directly enhanced endothelial cell survival, proliferation, and matrix metalloproteinases produc-

- tion and regulated angiogenesis. *J Immunol.* 2003;170:3369-3376.
32. Spandau UH, Toksoy A, Verhaart S, et al. High expression of chemokines Gro-alpha (CXCL-1), IL-8 (CXCL-8), and MCP-1 (CCL-2) in inflamed human corneas in vivo. *Arch Ophthalmol.* 2003;121:825-831.
  33. Natarajan K, Rajala MS, Chodosh J. Corneal IL-8 expression following adenovirus infection is mediated by c-Src activation in human corneal fibroblasts. *J Immunol.* 2003;170:6234-6243.
  34. Tran MT, Lausch RN, Oakes JE. Substance P differentially stimulates IL-8 synthesis in human corneal epithelial cells. *Invest Ophthalmol Vis Sci.* 2000;41:3871-3877.
  35. Strieter RM, Kunkel SL, Elner VM, et al. Interleukin-8: a corneal factor that induces neovascularization. *Am J Pathol.* 1992;141:1279-1284.
  36. Tanaka T, Kanai H, Sekiguchi K, et al. Induction of VEGF gene transcription by IL-1 beta is mediated through stress-activated MAP kinases and Sp1 sites in cardiac myocytes. *J Mol Cell Cardiol.* 2000;32:1955-1967.
  37. Valter MM, Wiestler OD, Pietsche T, Pietsch T. Differential control of VEGF synthesis and secretion in human glioma cells by IL-1 and EGF. *Int J Dev Neurosci.* 1999;17:565-577.
  38. Moses MA. The regulation of neovascularization of matrix metalloproteinases and their inhibitors. *Stem Cells.* 1997;15:180-189.
  39. Clark AF. New discoveries on the roles of matrix metalloproteinases in ocular cell biology and pathology. *Invest Ophthalmol Vis Sci.* 1998;39:2514-2516.
  40. Li D-Q, Lee S-B, Gunja-Smith Z, et al. Overexpression of collagenase (MMP-1) and stromelysin (MMP-3) by cultured pterygium head fibroblasts. *Arch Ophthalmol.* 2001;119:71-80.
  41. Leonardi A, Brun P, Abatangelo G, et al. Tear levels and activity of matrix metalloproteinase (MMP)-1 and MMP-9 in vernal keratoconjunctivitis. *Invest Ophthalmol Vis Sci.* 2003;44:3052-3058.
  42. Matsubara M, Girard MT, Cintron C, Fini ME. Differential roles for two gelatinolytic enzymes of the matrix metalloproteinases family in the remodelling cornea. *Dev Biol.* 1991;147:425-439.
  43. Fini ME, Cook JR, Mohan R. Proteolytic mechanisms in corneal ulceration and repair. *Arch Dermatol Res.* 1998;290(suppl):S12-S23.
  44. Fini ME, Parks WC, Rinehart WB, et al. Role of matrix metalloproteinases in failure to re-epithelialize after corneal injury. *Am J Pathol.* 1996;149:1287-1302.
  45. Afonso AA, Sobrin L, Monroy DC, et al. Tear fluid gelatinase B activity correlates with IL-1 $\alpha$  concentration and fluorescein clearance in ocular rosacea. *Invest Ophthalmol Vis Sci.* 1999;40:2506-2512.
  46. Kenney MC, Chwa M, Alba A, et al. Localization of TIMP-1, TIMP-2, TIMP-3, gelatinase A and gelatinase B in pathological human corneas. *Curr Eye Res.* 1998;17:238-246.
  47. Li DQ, Lokeshwar BL, Solomon A, et al. Regulation of MMP-9 production by human corneal epithelial cells. *Exp Eye Res.* 2001;73:449-459.
  48. Jasser MZ, Mitchell PG, Cheung HS. Induction of stromelysin-1 and collagenase synthesis in fibrochondrocytes by tumor necrosis factor-alpha. *Matrix Biol.* 1994;14:241-249.
  49. Mitchell PG, Cheung HS. Protein kinase regulation of tumor necrosis factor alpha stimulated collagenase and stromelysin message levels in chondrocytes. *Biochem Biophys Res Commun.* 1993;196:1133-1142.
  50. Mohan MJ, Seaton T, Mitchell J, et al. The tumor necrosis factor-alpha converting enzyme (TACE): a unique metalloproteinase with highly defined substrate selectivity. *Biochemistry.* 2002;41:9462-9469.
  51. Catrina AI, Lampa J, Ernestam S, et al. Anti-tumour necrosis factor (TNF)-alpha therapy (etanercept) down-regulates serum matrix metalloproteinase (MMP)-3 and MMP-1 in rheumatoid arthritis. *Rheumatology (Oxford).* 2002;41:484-489.
  52. Schulz S, Schagdarsurengin U, Suss T, et al. Relation between the tumor necrosis factor-alpha (TNF-alpha) gene and protein expression, and clinical, biochemical, and genetic markers: age, body mass index and uric acid are independent predictors for an elevated TNF-alpha plasma level in a complex risk model. *Eur Cytokine Netw.* 2004;15:105-111.
  53. Chorinchath BB, Kong LY, Mao L, McCallum RE. Age-associated differences in TNF-alpha and nitric oxide production in endotoxic mice. *J Immunol.* 1996;156:1525-1530.
  54. Han D, Hosokawa T, Aoike A, Kawai K. Age-related enhancement of tumor necrosis factor (TNF) production in mice. *Mech Ageing Dev.* 1995;84:39-54.
  55. Girard MT, Matsubara M, Fini ME. Transforming growth factor- $\beta$  and interleukin-1 modulate metalloproteinase expression by corneal stromal cells. *Invest Ophthalmol Vis Sci.* 1991;32:2441-2454.
  56. Librach CL, Feigenbaum SL, Bass KE, et al. Interleukin-1 beta regulates human cytotrophoblast metalloproteinase activity and invasion in vitro. *J Biol Chem.* 1994;269:17125-17131.
  57. Nelimarkka LO, Nikkari ST, Ravanti LS, et al. Collagenase-1, stromelysin-1 and 92 kDa gelatinase are associated with tumor necrosis factor-alpha induced morphological change of human endothelial cells in vitro. *Matrix Biol.* 1998;17:293-304.
  58. Bond M, Fabunmi RP, Baker AH, Newby AC. Synergistic upregulation of metalloproteinase-9 by growth factors and inflammatory cytokines: an absolute requirement for transcription factor NF-kappa B. *FEBS Lett.* 1998;435:29-34.
  59. Matsubara M, Zieske JD, Fini ME. Mechanism of basement membrane dissolution preceding corneal ulceration. *Invest Ophthalmol Vis Sci.* 1991;32:3221-3237.
  60. Kenney MC, Chwa M. Abnormal extracellular matrix in corneas with pseudophakic bullous keratopathy. *Cornea.* 1990;9:115-121.
  61. Solomon A, Li D-Q, Li D-Q, et al. Doxycycline inhibition of the interleukin-1 system in the corneal epithelium. *Invest Ophthalmol Vis Sci.* 2000;41:2544-2557.
  62. Sobrin L, Liu Z, Monroy DC, et al. Regulation of MMP-9 activity in human tear fluid and corneal epithelial culture supernatant. *Invest Ophthalmol Vis Sci.* 2000;41:1703-1709.