Ocular Surface Reconstruction

From Tissue Transplantation to Cell Therapy

Abraham Solomon, MD

Abstract: The most difficult part in ocular surface reconstruction for total limbal stem cell deficiency is restoring a healthy and stable corneal epithelium. Recently, there has been a shift toward a cellular-based transplantation that eliminates the need for harvesting large amounts of limbal tissues from a living donor. The autologous oral epithelium can be used as a source for ocular surface reconstruction instead of the limbal epithelial cells. This paper describes the method of harvesting autologous oral epithelial cells, culturing the cells on the amniotic membrane, and transplanting the amniotic membrane with the cultured oral epithelial cells on the ocular surface after removal of the fibrovascular scar tissue. Once the corneal epithelium is stable, penetrating keratoplasty may be performed at a later stage to restore the corneal clarity.

(*Tech Ophthalmology* 2009;7: 118–123)

TABLE 1. Treatment Strategies in Ocular Surface Diseases With Limbal Deficiency: A Multi-Step Approach

Steps	Description
1	Improving the ocular surface health (tear film, blepharitis, inflammation, recurrent epithelial erosions, and chronic ulcers, lids, and lashes)
2	Surgical procedures
	Fornix reconstruction and removal of fibrovascular tissues
	Creating a stable surface epithelium
	Replacing the opaque cornea
3	Maintaining ocular surface defenses, epithelial integrity, and corneal transparency

HISTORICAL REVIEW

Ocular surface diseases with partial or total stem cell deficiency can usually be distinguished into 2 types: (*a*) diseases with a conjunctivalized cornea, where there is a viable tear film and the surface is wet, and (*b*) a completely dry and keratinized ocular surface. The former may be subject to a series of procedures collectively termed ocular surface reconstruction, whereas in the latter, only keratoprosthesis can be performed. This paper will discuss the latest advances in ocular surface reconstruction and will focus on the shift from tissue transplantation, where autologous or allogenic limbal tissue is transplanted, to cell-based therapy, where epithelial cells are isolated and transplanted to the ocular surface using different carriers.

The treatment strategy in ocular surface reconstruction involves a multistep approach (Table 1). Improving the ocular surface health is the first step, which includes managing tear film problems, controlling blepharitis, suppressing inflammation, and treating recurrent corneal epithelial erosions and chronic ulcers. The second step includes the major surgical procedures, which start with reconstruction of the fornices and symblepharon repair and lid surgery to repair entropion. The next surgical step, which is the most challenging part in ocular surface reconstruction is aimed at creating a stable corneal epithelium. This includes autologous or allogenic transplantation of limbal tissue or transplantation of cultured epithelial cells that were expanded ex vivo on a carrier. These procedures will be further discussed in the following paragraphs. If a stable ocular surface was established and the corneal stroma is opaque, the next surgical step is corneal transplantation. The third step is maintaining the ocular surface defense mechanisms by continuous attention to the tear film, lid problems, and epithelial integrity (Table 1).

The mainstay of ocular surface reconstruction involves the creation of a stable surface epithelium. Two major approaches are available today to establish this goal (Table 2). The first approach involves tissue transplantation, whereas the second is based on cell therapy that involves ex vivo cultured epithelial cells.

Tissue transplantation involves transplantation of the limbal region, which may be harvested either from the contralateral healthy eye (autologous limbal transplantation), a living related donor, or a cadaveric source (allogenic limbal transplantation). Autologous limbal transplantation was first described by Kenyon and Tseng[1] in 1989 (Table 3) and is probably the most successful surgical procedure in ocular surface reconstruction. However, this procedure is not suitable in cases of bilateral limbal deficiency and may be avoided in patients who are afraid of operating on their only eye. The safety and favorable results of this procedure have been demonstrated in many studies.

Allogenic limbal transplantation is performed in cases of bilateral limbal deficiency.[2] Its disadvantages include the need for a long-term systemic immune suppression, a high incidence of graft rejection, and gradual loss of the donor cells with time.

TABLE 2. Techniques for Creating a Stable Ocular Surface Epithelium

Tissue transplantation
Autologous limbal transplantation
Allogenic limbal transplantation
Cell transplantation (ex vivo cultured epithelial cells)
Limbal epithelial cells
Autologous
Allogenic
Cadaveric
Living related
Oral mucosal epithelial cells
Autologous

From the Department of Ophthalmology, Hadassah–Hebrew University Medical Center, Jerusalem, Israel.
Address correspondence and reprint requests to Abraham Solomon, MD, Department of Ophthalmology, Hadassah–Hebrew University Medical Center, Jerusalem, Israel (e-mail: dr.avi.solomon@gmail.com).

TABLE 3. Evolution of Ocular Surface Reconstruction Surgery

Transplantation type	Year	Authors	Contribution
Tissue transplantation	1977	Thoft[3]	Conjunctival autograft
	1984	Thoft[4]	Keratoepithelioplasty (cadaver)
	1989	Kenyon and Tseng[1]	Conjunctival limbal autograft
	1994	Tsai and Tseng[2]	Keratolimbal allograft (cadaver)
	1995	Kim and Tseng[2]	Amniotic membrane transplantation
	1996	Holland[5]	Conjunctival limbal allograft (living related)
Cell transplantation	2000	Tsai et al[6]	Ex vivo expansion on intact AM
	2000	Schwab et al[7]	Ex vivo expansion on 3T3 and then AM
	2001	Rama et al[8]	Ex vivo expansion of limbal stem cells on fibrin as a carrier
	2003	Kinoshita et al[9]	Ex vivo expansion on denuded AM with 3T3 on the plastic plate
	2004	Nishida et al[10]	Ex vivo expansion on 3T3 using a temperature-sensitive plastic plate without a carrier

AM indicates amniotic membrane.

The cumulative incidence of allogenic graft failure may reach 50% in 3 years.[11]

Owing to the disadvantages that are associated with limbal tissue transplantation, different groups and investigators have explored the possibilities of cell therapy. This involves culturing donor epithelial cells from various sources on different culture substrates, which sometimes also serve as carriers for transplantation. Transplantation of cultured autologous limbal epithelial stem cells on the human amniotic membrane was first described by Tsai et al.[6] Another system was described by Rama et al[8] in 2001 (Table 3) where limbal epithelial stem cells were cultured on fibrin substrate.

There are several types of ex vivo stem cell expansion cultures.[12] The source of the cultured cells can be either autologous or allogenic. The autologous culture is derived from a small limbal explant, measuring 1 to 2 mm from the healthy contralateral eye. This reduces the risk to the healthy donor eye compared with the potential risk involved in autologous limbal transplantation, where the harvested tissue includes 30% to 40% of the entire limbal circumference. The allogenic culture may be derived from a small limbal explant from a living related donor, preferably HLA-matched, or from a cadaveric corneoscleral rim.

Various carriers have been described for the cultured limbal cells, which include the human amniotic membrane, fibrin gel, a synthetic temperature sensitive polymer, a contact lens, and even the anterior lens capsule.

There are several benefits of the ex vivo expansion stem cell culture. The culture system maintains the progenitor stem cell properties of limbal epithelial cells and, at the same time, excludes immunogenic elements in the limbal environment (such as fibroblasts, the vascular endothelium, and Langerhans cells). In addition, the amniotic membrane provides a human basement membrane and together with the epithelial cells, forms a physiological epithelial basement membrane unit for transplantation. The amniotic membrane is also a convenient carrier from the laboratory to the operating room and is easily handled and fixed to the ocular surface with either sutures or with biological glue.

In recent years, a new source of epithelial cells has emerged into ocular surface reconstruction: the oral mucosa epithelial cells. Studies performed by Kinoshita's group demonstrated that cultured oral epithelial cells on the amniotic membrane can be transplanted in an animal model of total limbal deficiency. These cells resembled normal corneal epithelial cells and resulted in a clear cornea and a stable corneal surface.[9] Following the successful animal studies, autologous oral epithelial cells were cultured on the amniotic membrane and were successfully transplanted in patients with severe ocular surface disorders and bilateral stem cell deficiency.[13] There are several advantages to this method. The autologous source of the epithelial cells precludes the need for systemic immune suppression, which is required in allogenic limbal transplantation often performed in bilateral limbal deficiency. The proliferative capacity of oral epithelial cells is higher than that of the ocular surface epithelium. In addition, it is possible to repeat this procedure several times and to take more oral biopsies in case of a failure.

EX VIVO CULTURE SYSTEM

The ex vivo culture systems require several key steps, including biopsy of limbal or oral mucosal epithelial cells (Fig. 1), preparation of the culture as either an explant culture or a suspension of single cells that are separated and then seeded on to the carrier, the use of a proper culture medium, preparation of the carrier for the cells in a special culture insert that can be easily handled and transferred to the operating room (Fig. 2),

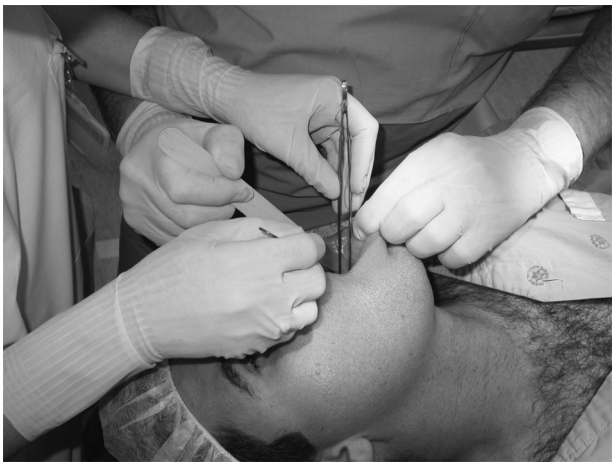

FIGURE 1. Harvesting oral biopsy specimen for oral epithelial transplantation onto the ocular surface after ex vivo culture system (Reprinted with permission from SLACK Incorporated: Ocular Surgery News).

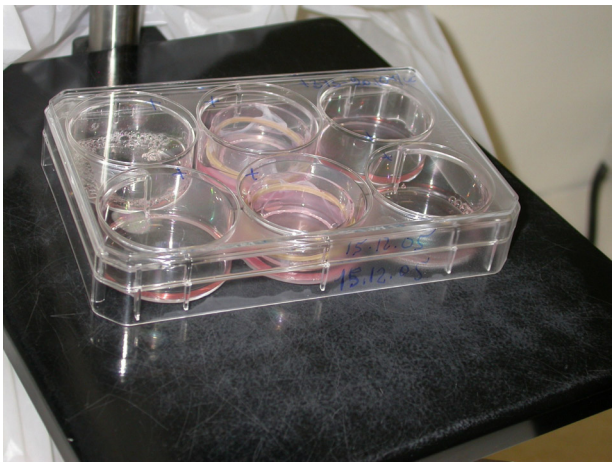

FIGURE 2. Culture inserts of the amniotic membrane with the cultured oral epithelial cells (Reprinted with permission from SLACK Incorporated: Ocular Surgery News).

and additional methods such as the 3T3 feeder layer and air lifting to promote stratification of the cells.

The explant culture system includes a small piece from a limbal biopsy that is placed over the basement membrane side of the human amniotic membrane (Fig. 3). The human amniotic membrane serves both as a substrate and a carrier. The explant is submerged in a special culture medium containing several growth factors and agents that promote epithelial growth and serum that may be prepared from the patient's blood. The culture is kept for 2 to 3 weeks, and air lifting during the last week is performed to promote stratification and differentiation of the cells. An alternative culture method is preparing a single-cell suspension by enzymatic separation of the epithelial cells from the tissue, which is then seeded over the carrier (Fig. 4).

The most popular and convenient carrier is the human amniotic membrane. The amniotic membrane was shown to promote epithelial expansion and to maintain the progenitor properties of limbal epithelial stem cells. It may be denuded from its original amniotic epithelium, or the amniotic epithelium may be left intact. The amniotic membrane is readily available from placentas obtained from cesarean deliveries and is convenient to handle as a carrier during surgery by suturing or by gluing to the ocular surface. An elegant alternative to the amniotic membrane was recently described by Nishida et al,[10] who used a temperature-sensitive polymer membrane. The epithelial cells readily adhered to and proliferated on the polymer membrane in normal culture conditions at 37°C. At room temperature, the epithelial sheet detaches from the polymer and is then transferred and applied over the ocular surface.

SURGICAL TECHNIQUE

The surgical technique of cultured cell transplantation includes the usual removal of corneal fibrovascular tissue (Figs. 5A, B), superficial keratectomy (Figs. 5C, D), and removal of subconjunctival tissue 360 degrees, up to 5 to 7 mm from the limbus (Fig. 5E). This may be followed by application of 0.02% mitomycin C for 2 minutes (Fig. 5F), followed by irrigation. After the cornea and the perilimbal sclera are clean and exposed, the amniotic membrane with the cultured epithelial cells is removed from the culture insert, spread over the ocular surface (Fig. 5G), and sutured to the sclera with continuous and interrupted 10-0 nylon sutures (Fig. 5H). Temporary tarsorrhaphy is performed at the end of the procedure and kept for at least 2 weeks to protect the transplanted epithelial cells and to ensure proper integration of the cells and the amniotic membrane on the ocular surface. The sutures are removed after 2 weeks and when full epithelialization

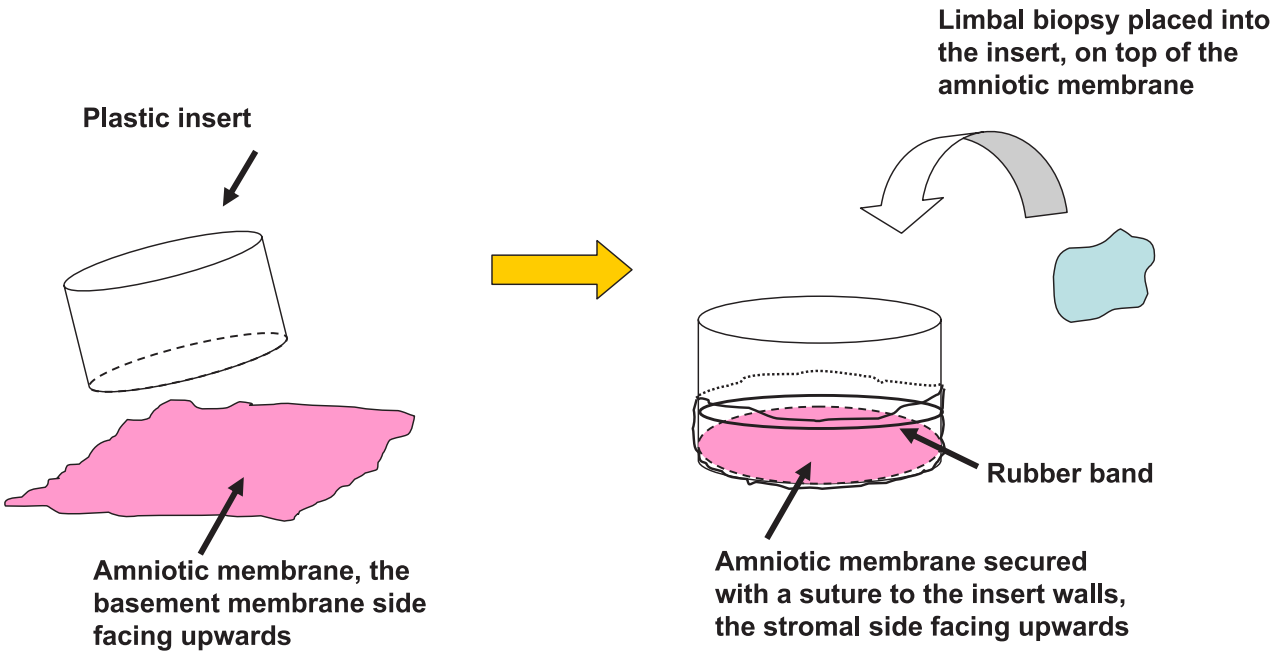

FIGURE 3. Schematic representation of the explant culture system. A small limbal biopsy specimen is placed on the human amniotic membrane in a culture ring insert.

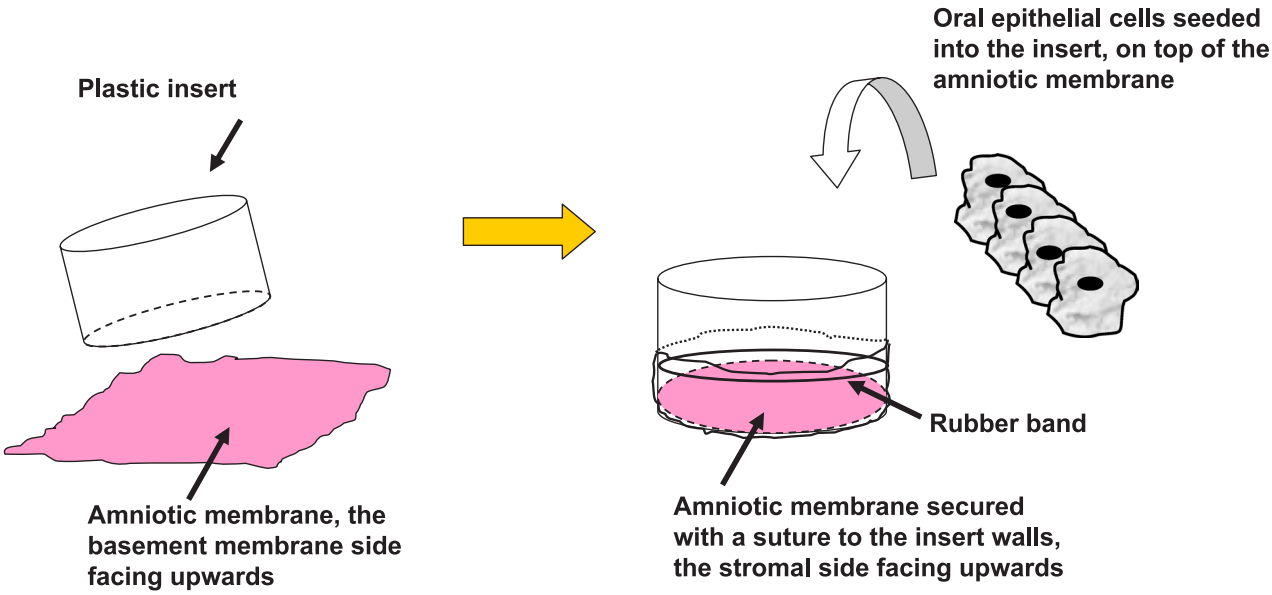

FIGURE 4. Schematic representation of the suspension culture system. Epithelial cells are enzymatically separated from the explant and are seeded on the human amniotic membrane.

is noted. Postoperatively, topical corticosteroids and antibiotics are administered 4 to 6 times daily.

DISCUSSION

The clinical outcome of tissue transplantation and cell therapy to the ocular surface was described in several studies over the past few years. The clinical parameters of a successful result are not clearly defined. The reported parameters in the literature include a stable transparent corneal epithelium, resolution of corneal conjunctivalization, resolution of persistent epithelial defects, and regression of corneal vascularization. Based on these parameters, the overall success rate in pooled data from studies that had been published during the years 1997 to 2006 was 77%, with a wide range of 33% to 100%.[12]

The long-term results of cultured oral epithelial transplantation seem favorable (Figs. 6 and 7), especially when corneal

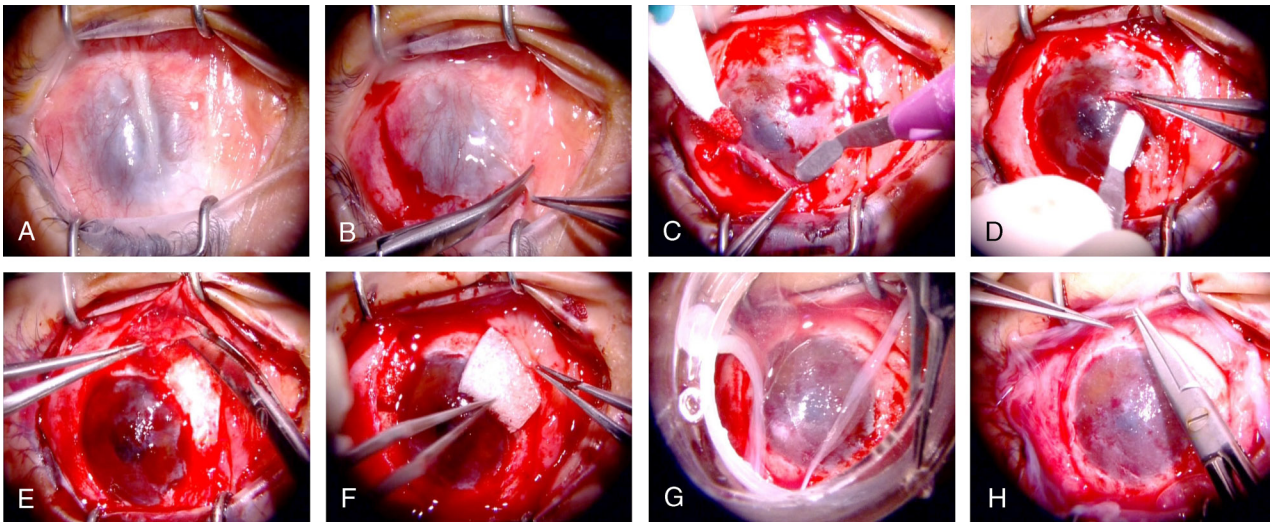

FIGURE 5. A, Ocular surface reconstruction of a patient with total stem cell deficiency after a chemical burn. Intraoperative photograph displaying extensive ocular surface disease with complete obliteration of the normal corneal surface. B, Initial surgical steps in the removal of the corneal fibrovascular tissue. C, Superficial keratectomy. D, Superficial keratectomy reveals the underlying cornea beneath the surface fibrovascular tissues. E, Removal of subconjunctival tissue 360 degrees, up to 5.0 to 7.0 mm distal to the limbus on the scleral side. F, Intraoperative photograph showing the application of 0.02% mitomycin C for 2 minutes, followed by copious irrigation with sterile balanced salt solution. G, After the cornea and the perilimbal sclera are clean and exposed, the human amniotic membrane with the cultured epithelial cells is removed from the culture insert, and it is spread over the recipient ocular surface. H, The human amniotic membrane with the cultured epithelial cells is spread over the recipient ocular surface and sutured to the sclera with continuous and interrupted 10-0 nylon sutures.

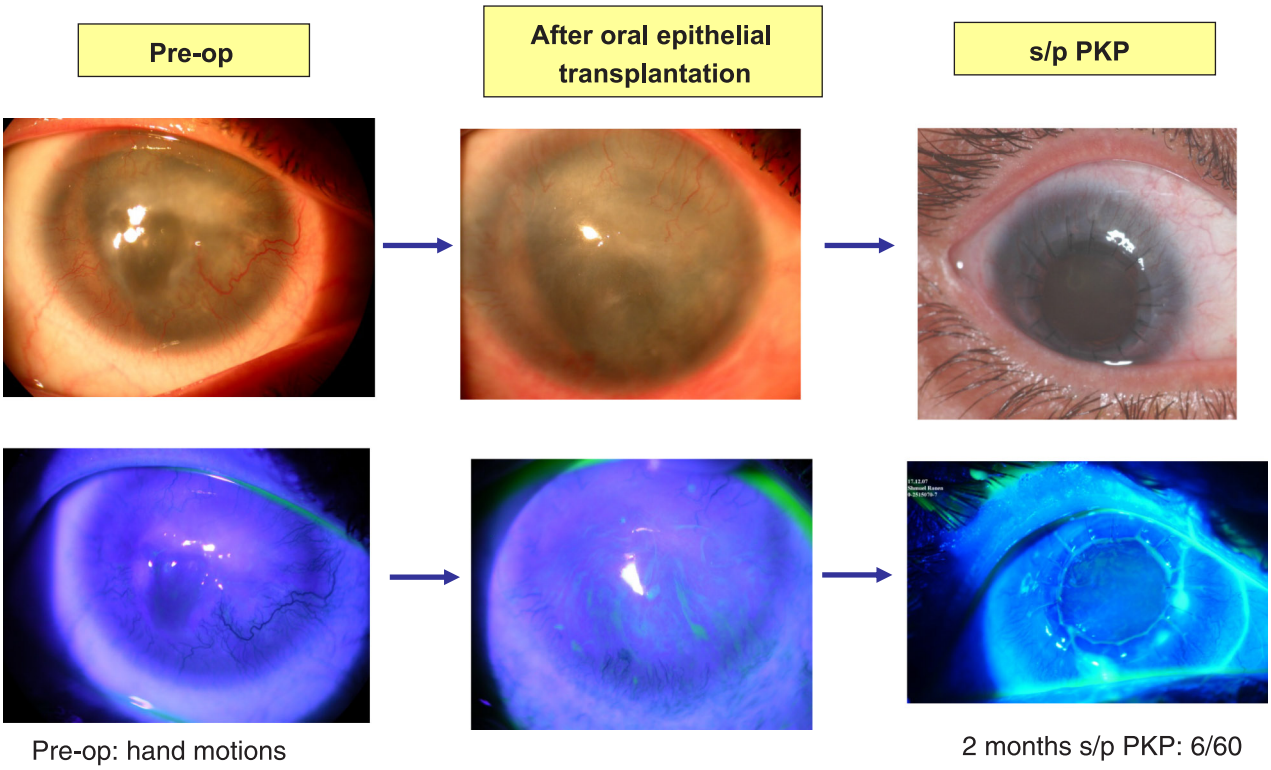

FIGURE 6. A patient with aniridia before and after oral epithelial transplantation followed by penetrating keratoplasty.

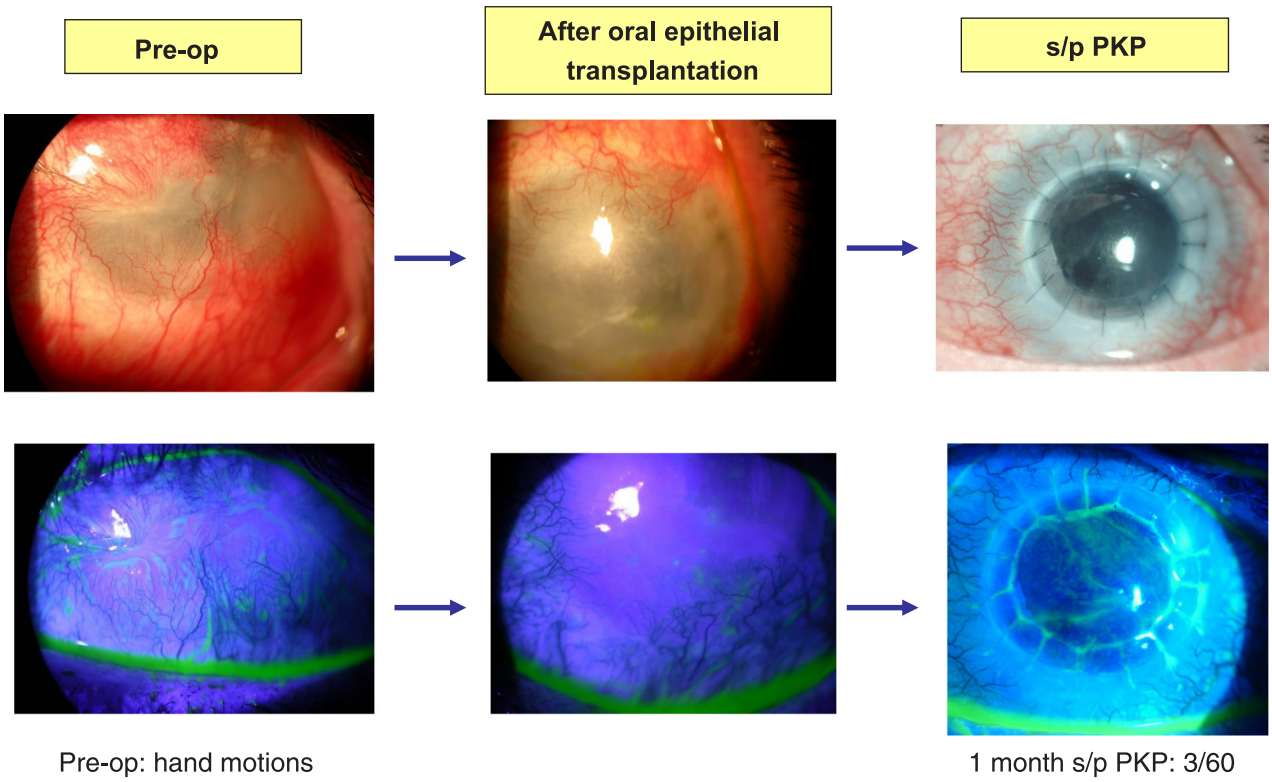

FIGURE 7. A patient with a bilateral chemical burn before and after oral epithelial transplantation followed by penetrating keratoplasty.

transplantation is performed at a later stage.[14] However, the number of reported cases in the literature is small, with a limited period of follow-up. Peripheral corneal vascularization was noted in patients after oral epithelial transplantation. Currently, it is not clear whether the transplanted oral epithelial cells survive on the ocular surface, and if indeed, some of the transplanted cells are progenitor cells that are capable of maintaining continued stability to the ocular surface epithelium. However, this procedure seems to be a promising solution for patients with severe bilateral stem cell deficiency, thus avoiding allogenic keratolimbal transplantation, with its high risk of graft rejection and the need for systemic immune suppression.

In conclusion, ocular surface reconstruction remains one of the most challenging areas in ophthalmology. It involves a multistaged, individually tailored approach, with the need for multiple complex surgical procedures. The last few years have seen a shift toward a cellular-based transplantation that eliminates the need for harvesting large amounts of limbal tissues from living donors or from the contralateral healthy eye. In addition, the oral epithelium seems to be a promising source for ocular surface reconstruction instead of the limbal epithelial cells. However, these procedures demand a dedicated tissue culture facility an skilled laboratory personnel, and their long-term efficacy still needs to be determined.

REFERENCES

1. Kenyon KR, Tseng SCG. Limbal autograft transplantation for ocular surface disorders. *Ophthalmology*. 1989;96:709–723.
2. Tsai RJF, Tseng SCG. Human allograft limbal transplantation for corneal surface reconstruction. *Cornea*. 1994;13:389–400.
3. Thoft RA. Conjunctival tranplantation. *Arch Ophthalmol*. 1977;95: 1425–1427.
4. Thoft RA. Keratoepithelioplasty. *Am J Ophthalmol*. 1984;97:1–6.
5. Holland EJ. Epithelial transplantation for the management of severe ocular disease. *Trans Am Ophthalmol Soc*. 1996;94:677–743.
6. Tsai RJ, Li LM, Chen JK. Reconstruction of damaged corneas by transplantation of autologous limbal epithelial cells. *N Engl J Med*. 2000;343:86–93.
7. Schwab IR, Reyes M, Isseroff RR. Successful transplantation of bioengineered tissue replacements in patients with ocular surface disease. *Cornea*. 2000;19:421–426.
8. Rama P, Bonini S, Lambiase A, et al. Autologous fibrin-cultured limbal stem cells permanently restore the corneal surface of patients with total limbal stem cell deficiency. *Transplantation*. 2001;72: 1478–1485.
9. Nakamura T, Endo K, Cooper LJ, et al. The successful culture and autologous transplantation of rabbit oral mucosal epithelial cells on amniotic membrane. *Invest Ophthalmol Vis Sci*. 2003;44:106–116.
10. Nishida K, Yamato M, Hayashida Y, et al. Corneal reconstruction with tissue-engineered cell sheets composed of autologous oral mucosal epithelium. *N Engl J Med*. 2004;351:1187–1196.
11. Solomon A, Ellies P, Anderson DF, et al. Long-term outcome of keratolimbal allograft with or without penetrating keratoplasty for total limbal stem cell deficiency. *Ophthalmology*. 2002;109:1159–166.
12. Shortt AJ, Secker GA, Notara MD, et al. Transplantation of ex vivo cultured limbal epithelial stem cells: a review of techniques and clinical results. *Surv Ophthalmol*. 2007;52:483–502.
13. Inatomi T, Nakamura T, Koizumi N, et al. Midterm results on ocular surface reconstruction using cultivated autologous oral mucosal epithelial transplantation. *Am J Ophthalmol*. 2006;141:267–275.
14. Inatomi T, Nakamura T, Kojyo M, et al. Ocular surface reconstruction with combination of cultivated autologous oral mucosal epithelial transplantation and penetrating keratoplasty. *Am J Ophthalmol*. 2006;142:757–764.